

Spontaneous lesions in the central nervous system of aging Syrian hamsters

Ingo Gerhauser¹, Heinrich Ernst², Wolfgang Baumgärtner¹, Paul-Georg Germann³, Peter Wohlsein¹



¹Department of Pathology, University of Veterinary Medicine Hannover

²Fraunhofer-Institute for Toxicology and Experimental Medicine, Hannover

³Nycomed Deutschland GmbH, Konstanz, Germany



Introduction

- **Syrian golden hamsters** (*Mesocricetus auratus*)
 - Permissive hibernator
- **Life expectancy** approximately 2 years
- **Pet and laboratory animals**
 - Research on activity rhythms
 - Inhalation studies
- **Background pathology** hardly investigated
- **Animal model** for age-related changes in other species ?
- **Aim of study**
 - Detection of spontaneous age-dependent lesions in the central nervous system

Material and Methods

- **520 Syrian Golden Hamsters** (*Mesocricetus auratus*)
 - Male and female
- **5 age groups**
 - 1, 3, 6, 12, 24 months
- **10 section levels**
- **Histology**
 - Hematoxylin-Eosin (HE), Luxol Fast Blue (LFB), Congo red, Periodic acid-Schiff reaction (PAS), Toluidin blue, Bielschowsky, Campbell-Switzer, von Kossa staining
- **Immunohistochemistry**
 - Glial fibrillary acidic protein (GFAP), Amyloid precursor protein (APP)



Results

- **Death** of 19% male and 37% female hamsters of last age group before end of the study
 - Severe signs of morbidity
- Age-dependent increase in **vacuolization**
 - Neuropil, not within the cytoplasm of neurons
- Age-dependent increase in **mineralization**
 - 51% male and 54% female 24-month-old hamsters

Results

- Neuronal **lipofuscin** deposition (LFB⁺, PAS⁺)
 - 96% male and 92% female 24-month-old hamsters
 - Meningeal **lipopigment** deposition
 - 16% male and 11% female 24-month-old hamsters
 - Meningeal **melanin/hemosiderin** deposition
 - 14% male and 13% female 24-month-old hamsters
 - **Melanocytes** (0-9%)
 - **Mast cells** (0-26%)
- } Young and old hamsters

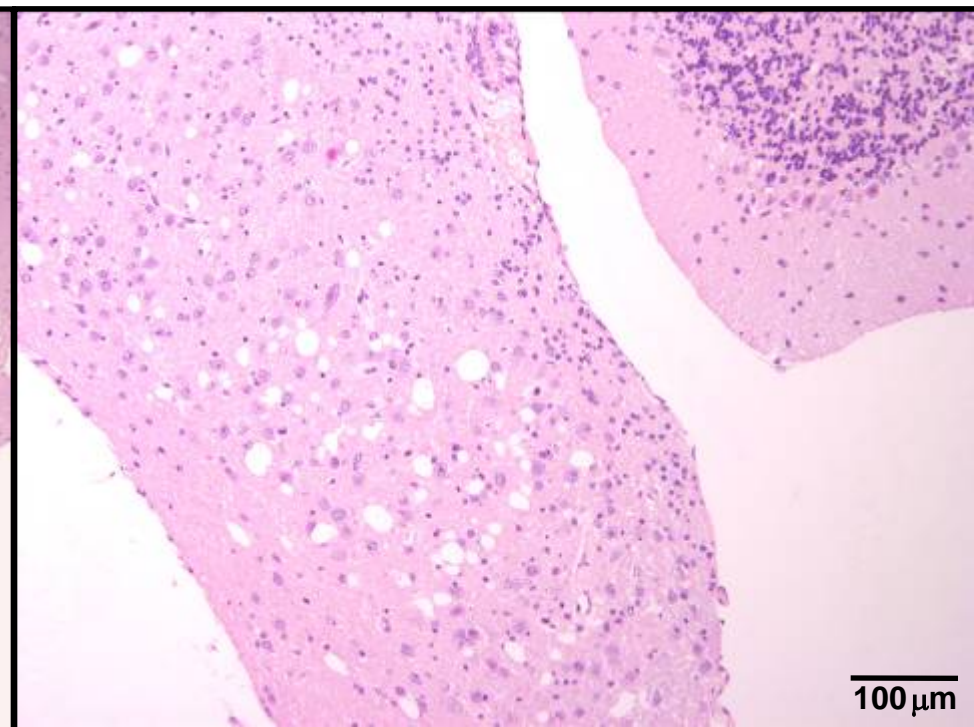
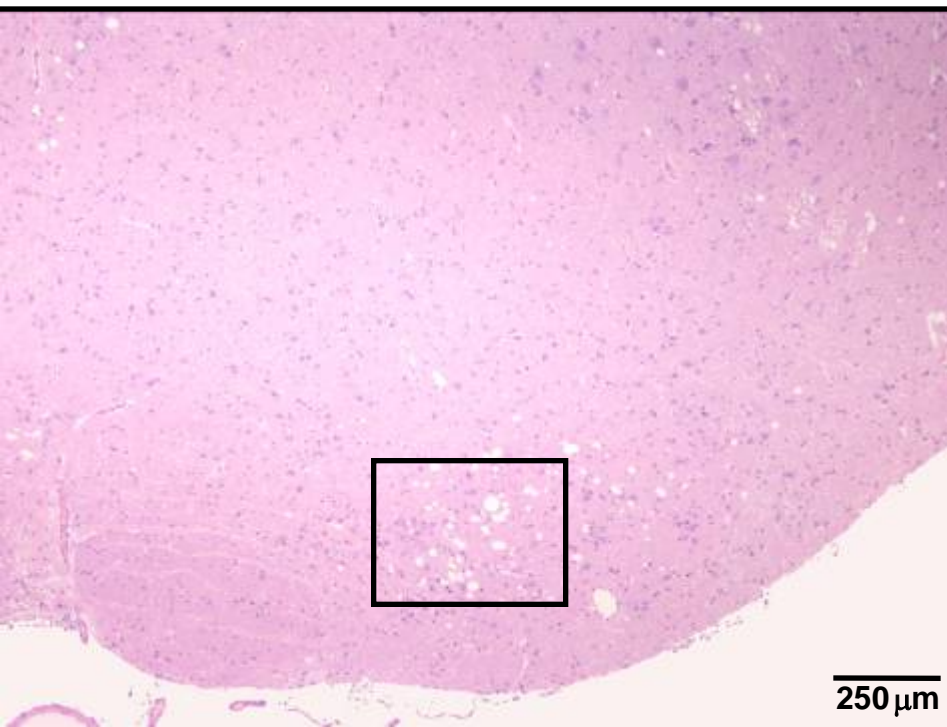
Results

- **Tumors** (n=5)
 - Pituitary adenoma (n=1), pituitary adenocarcinoma (n=3), lymphoma (n=1), blastoma (n=1)
- **Spheroids** (n=4)
- **Necrosis with gliosis** (n=3)
- **Meningoencephalitis** (n=2)
- Absence of demyelination, amyloid deposition, senile plaques, and neurofibrillary tangles

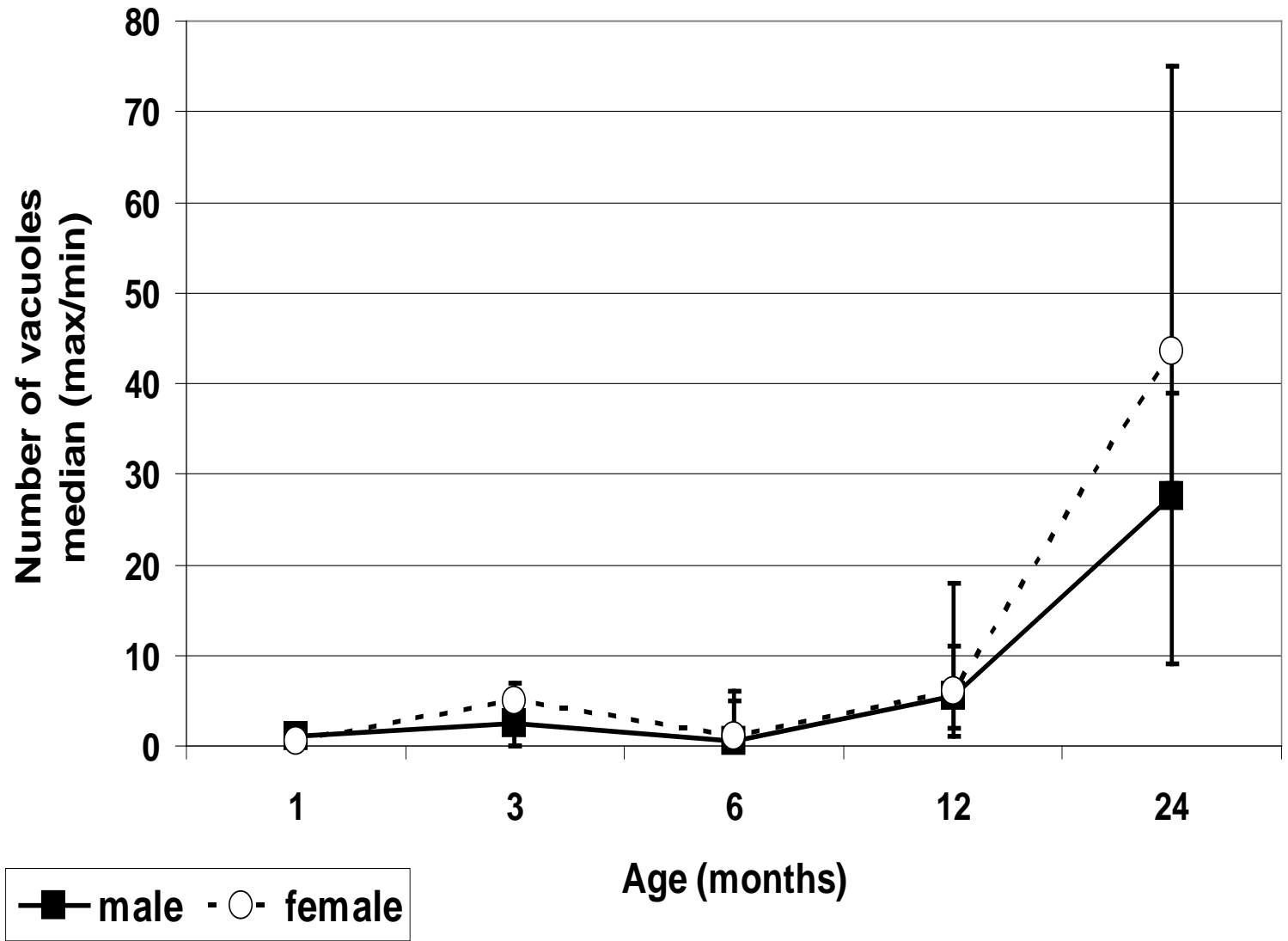
Vacuolization

- Vacuolization in the medulla oblongata

24-month-old female hamster



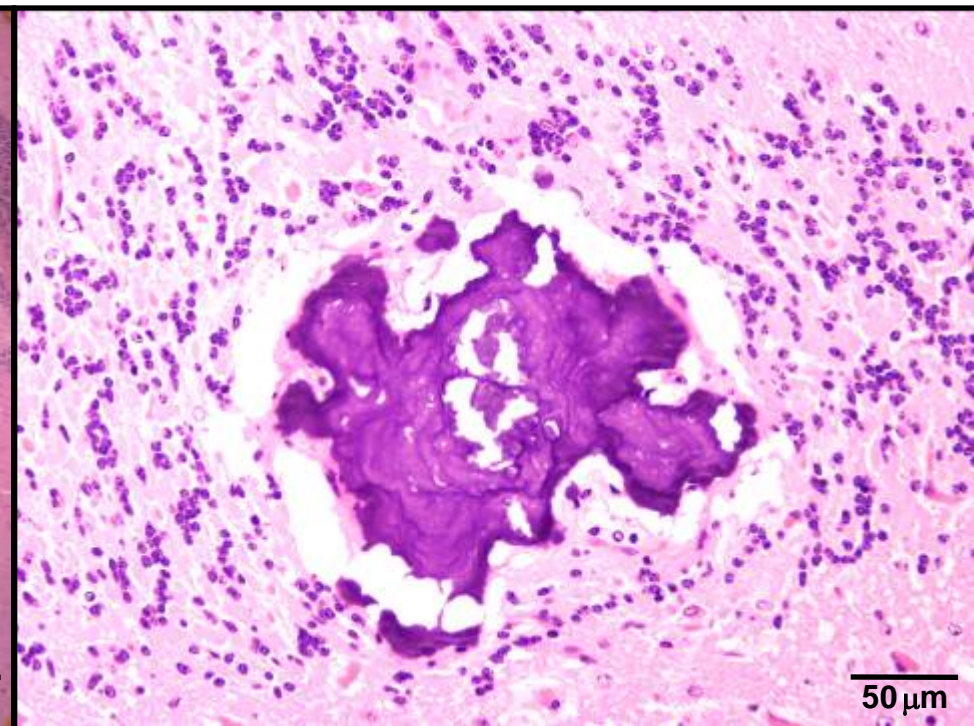
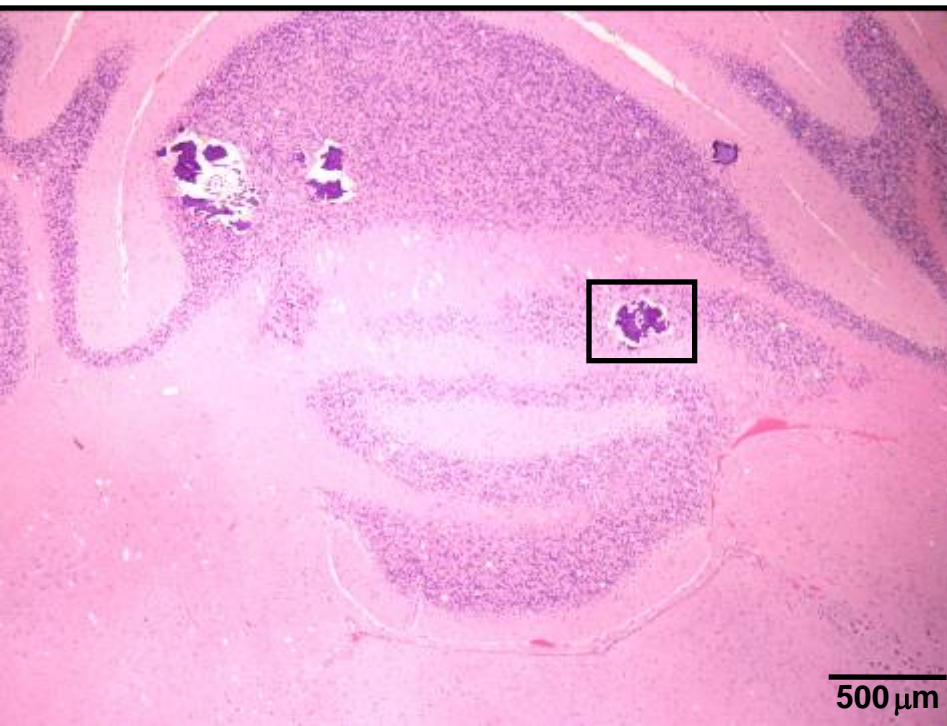Vacuolization



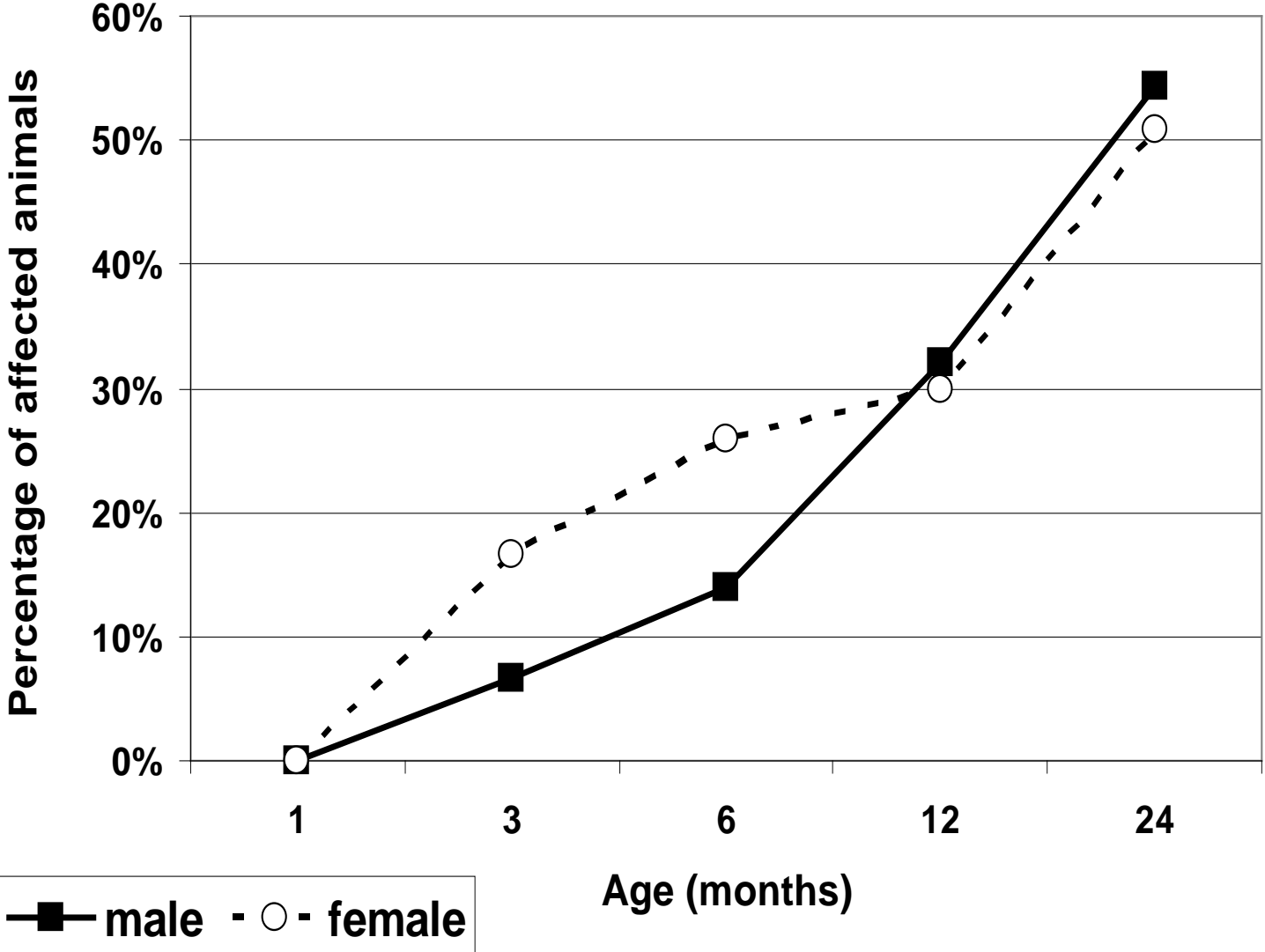
Mineralization

- Severe mineralization in cerebellum

24-month-old female hamster



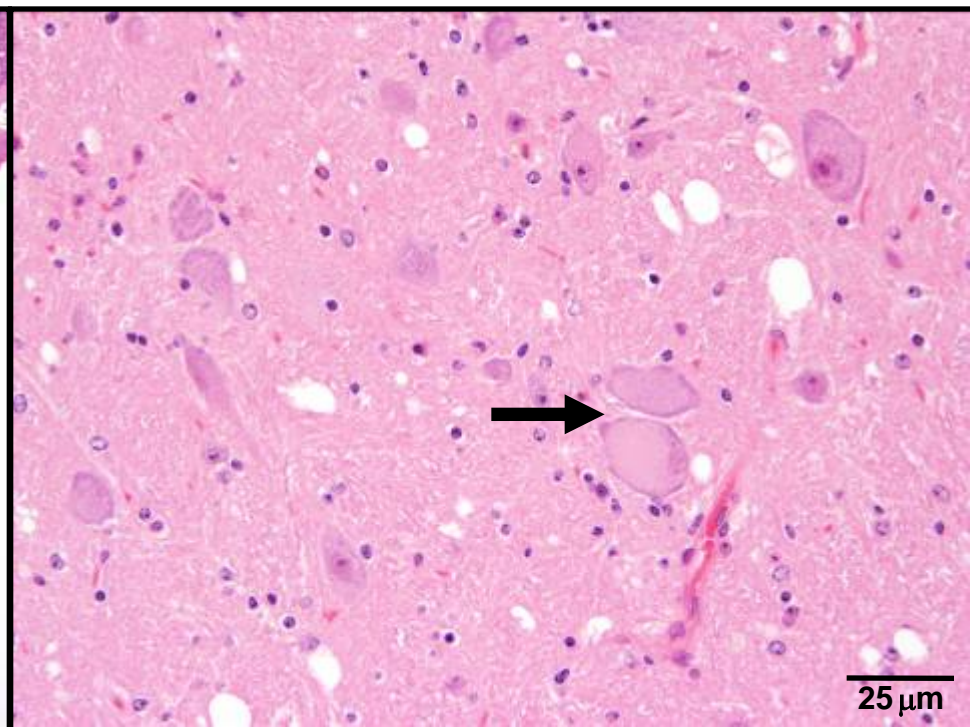
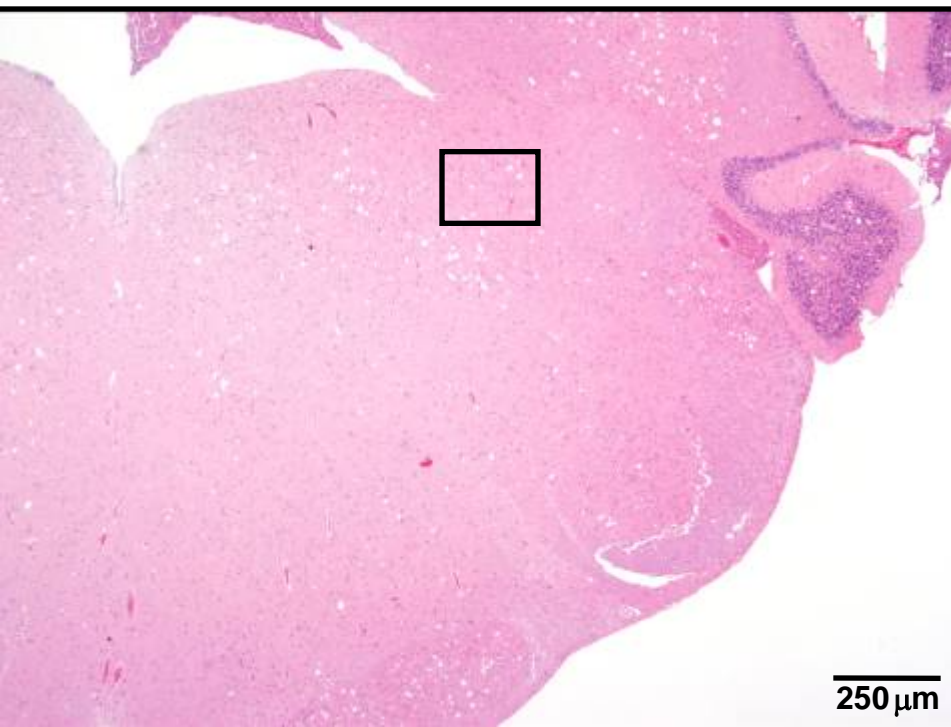
Mineralization



Pigments

- Intraneuronal deposition of a granular eosinophilic to yellowish material in the medulla oblongata

24-month-old female hamster

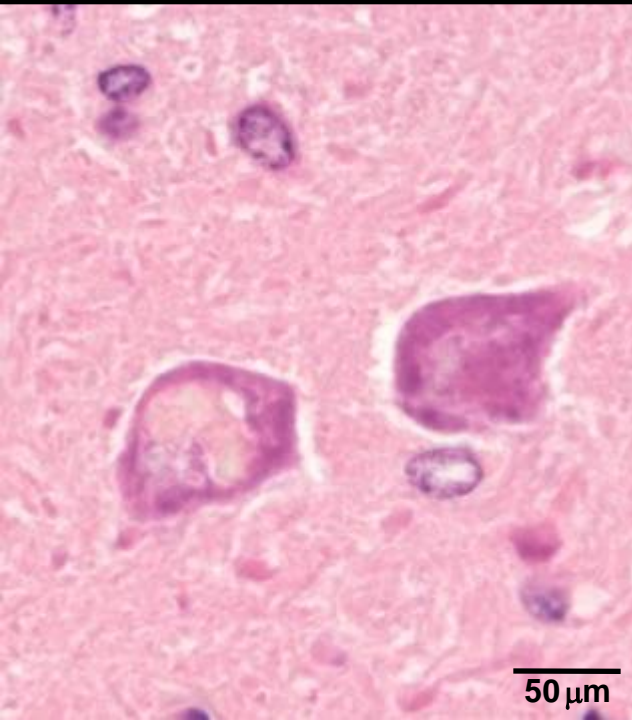


Pigments

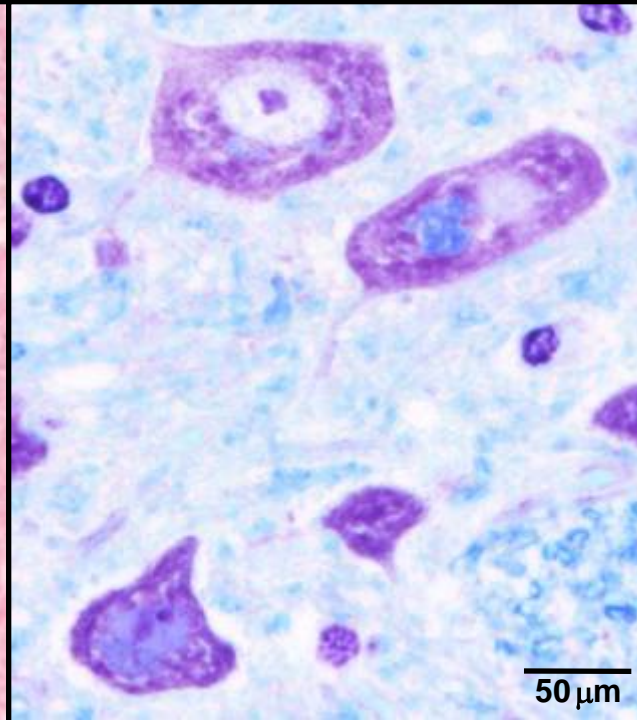
- Intraneuronal lipofuscin deposition
 - LFB and PAS positive

24-month-old female hamster

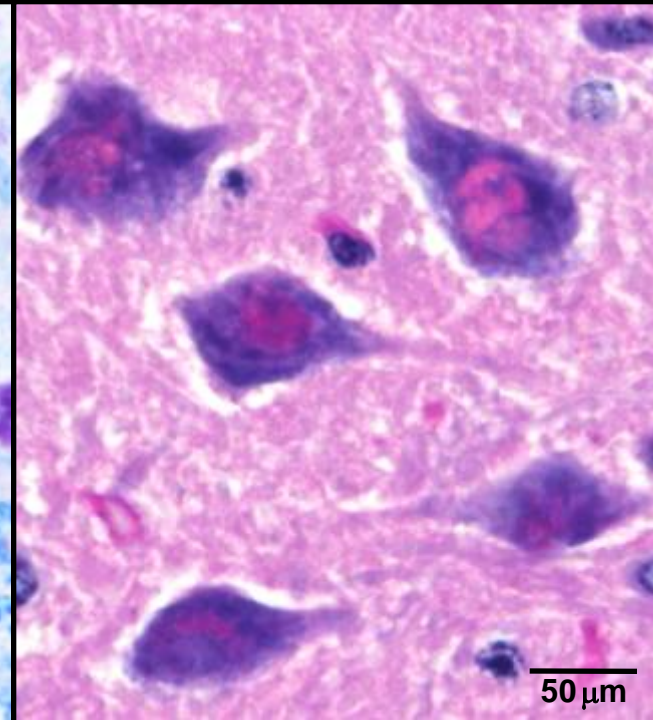
HE



LFB



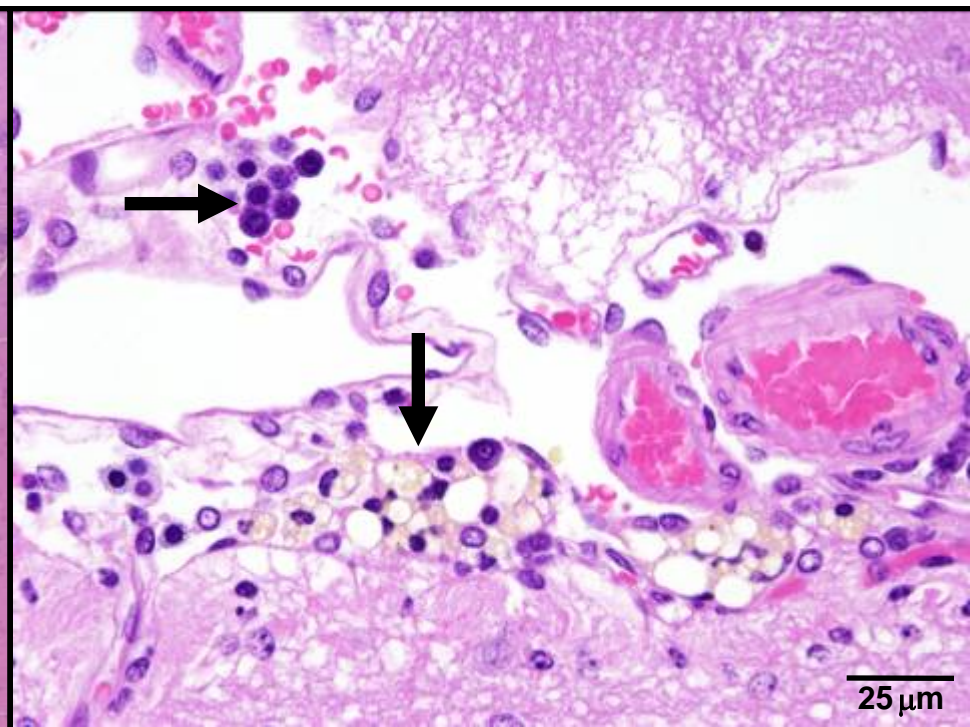
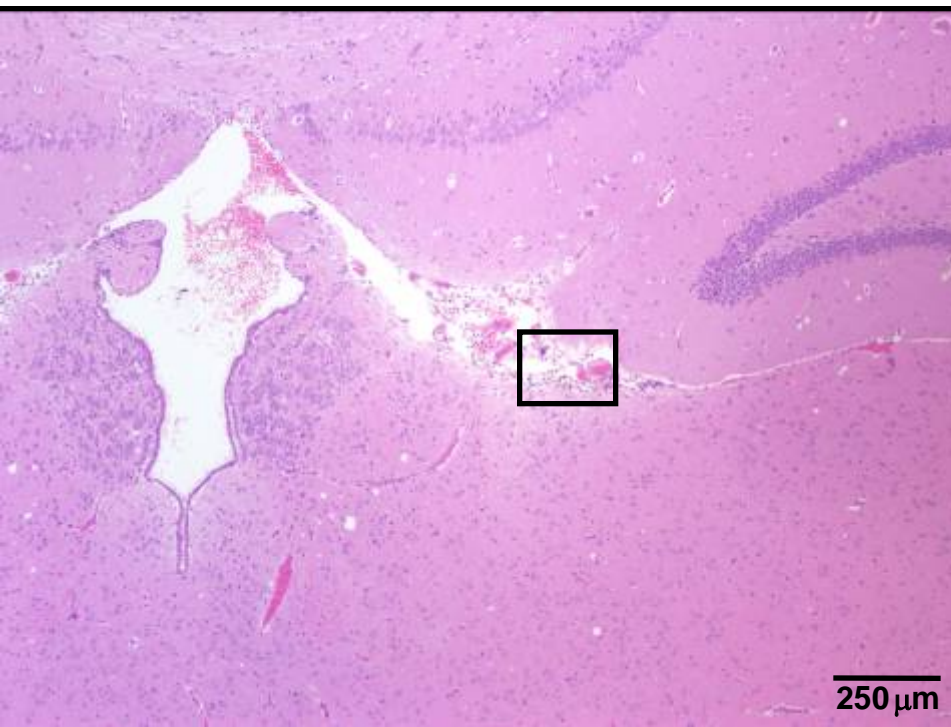
PAS



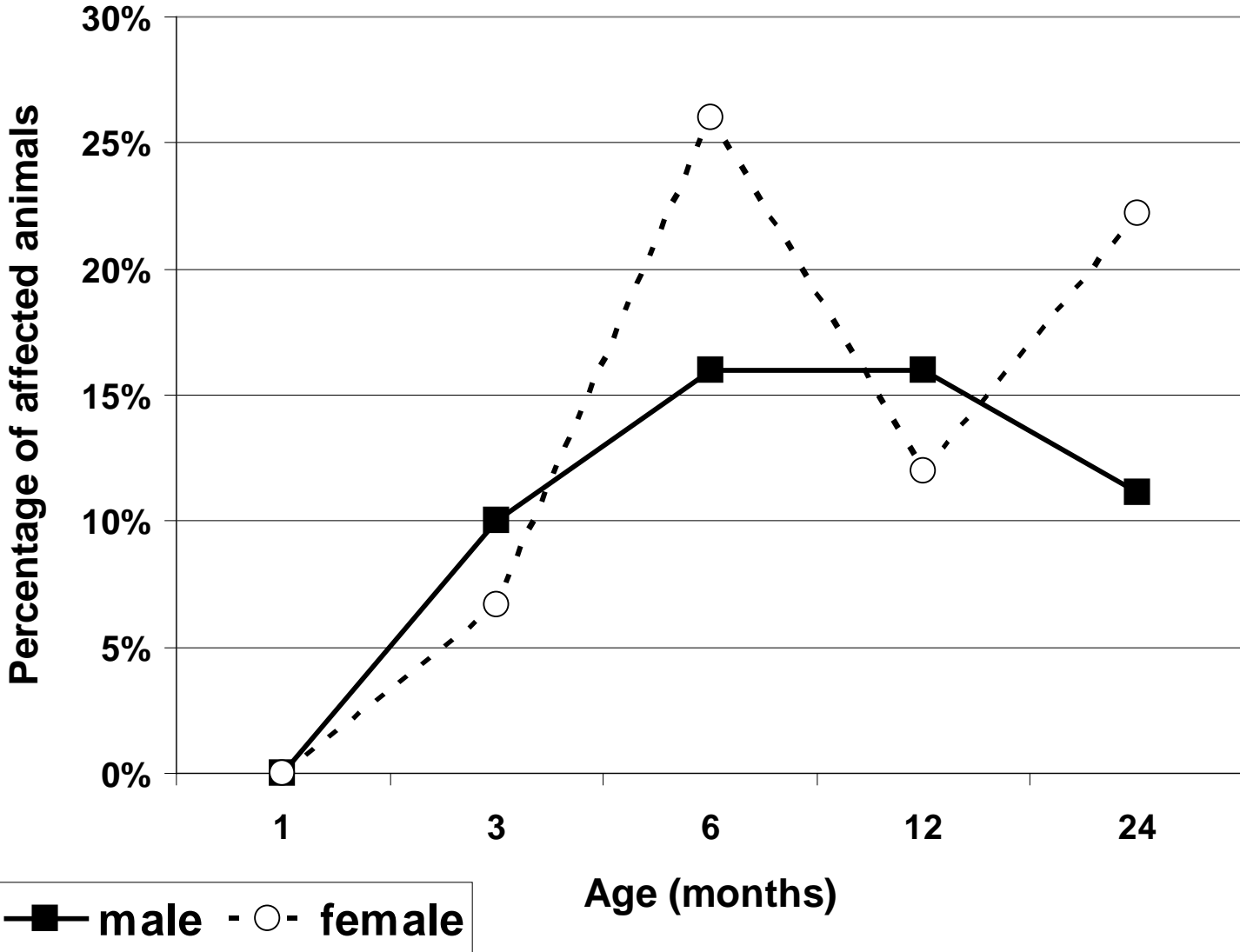
Pigments

- Lipopigment and mast cells in the meninx of the cerebrum

24-month-old male hamster



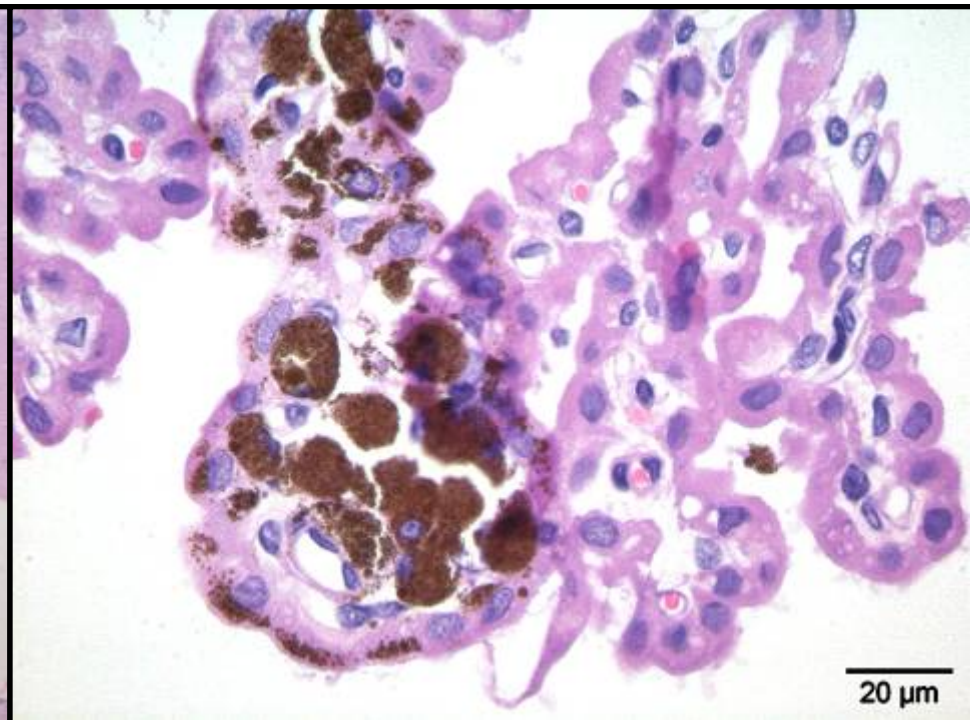
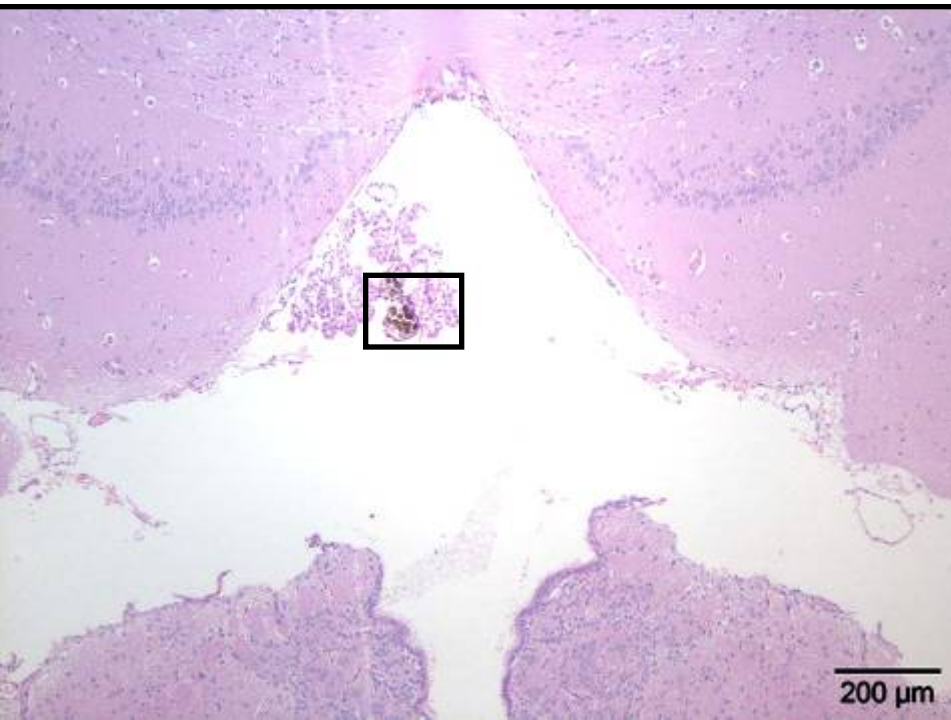
Mast cells



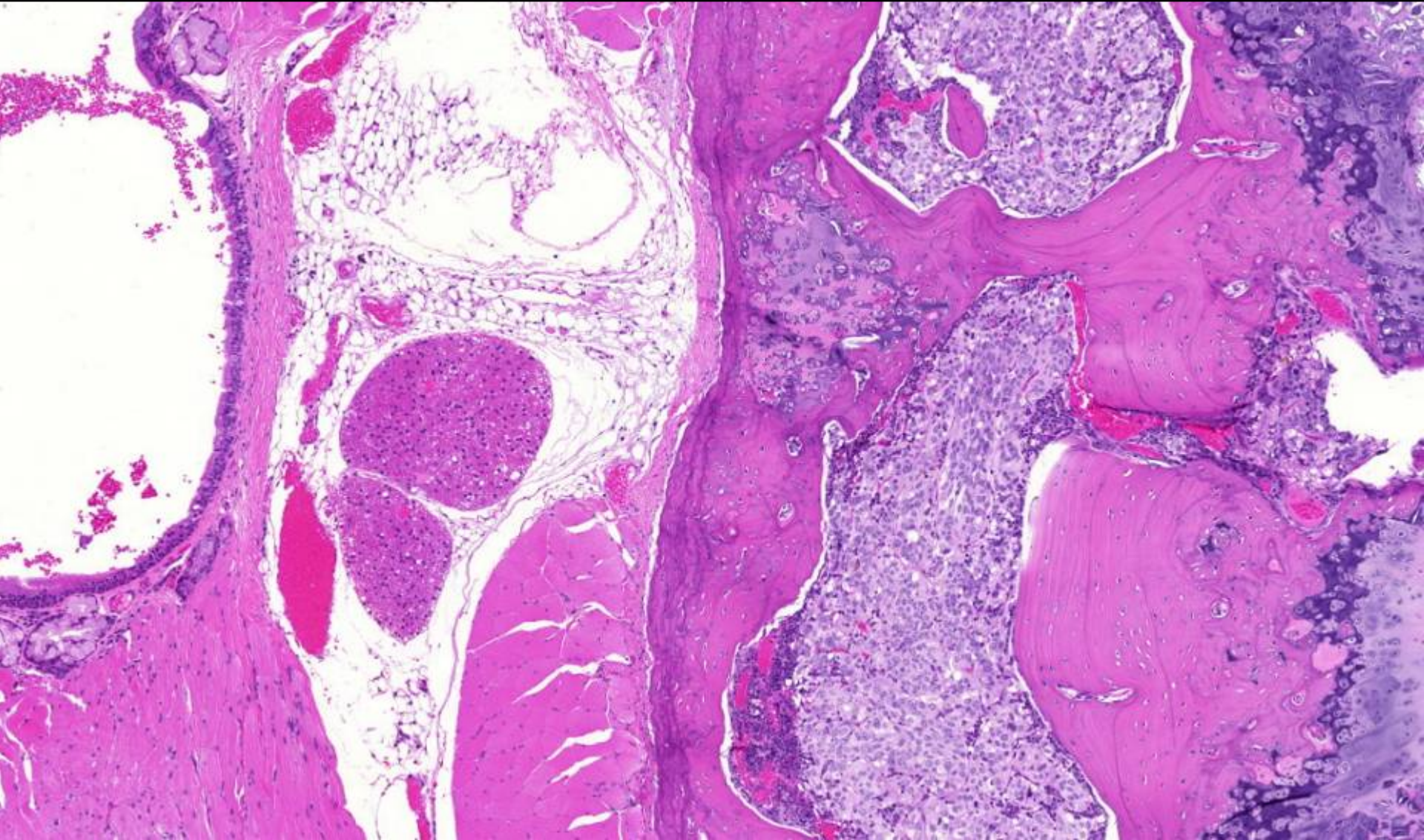
Pigments

- Melanocytes in the choroid plexus of the third ventricle

3-month-old female hamster



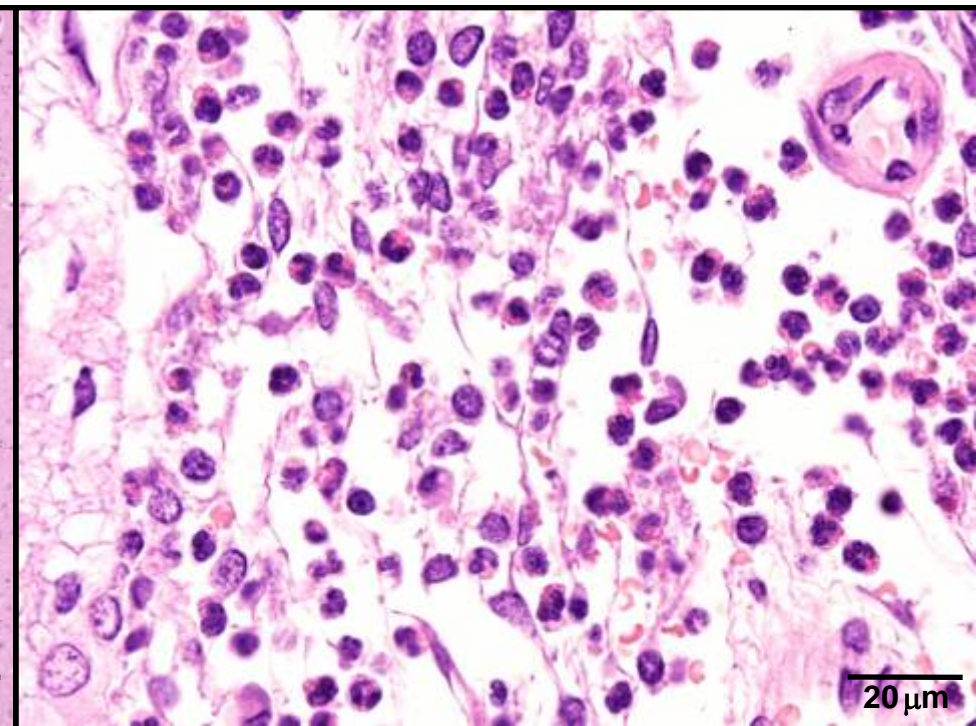
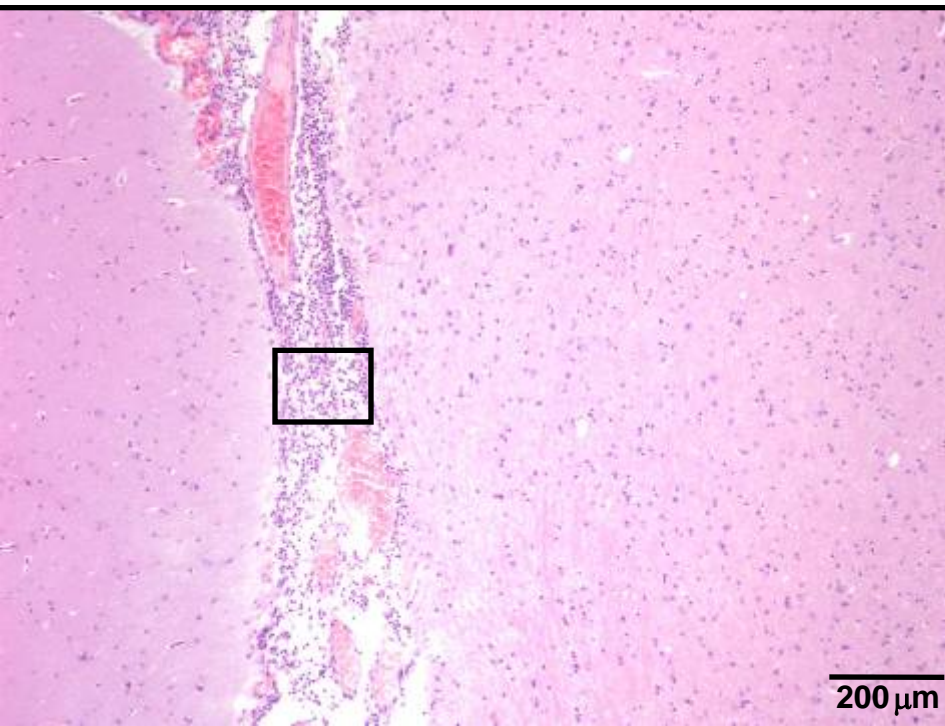
Tumor



Inflammation

- Suppurative meningitis in the mesencephalon

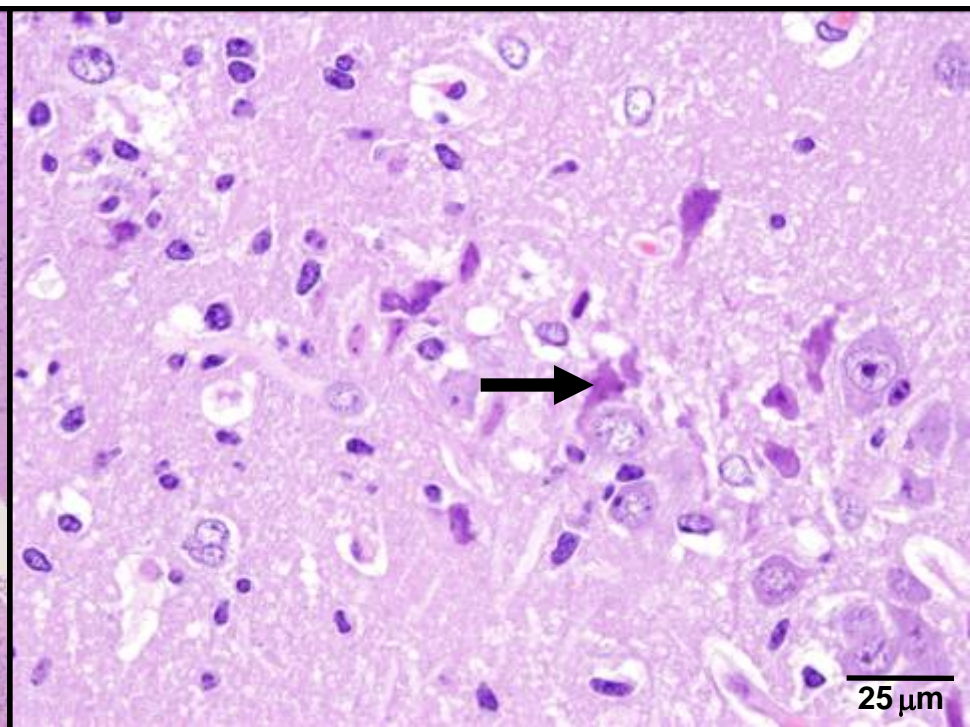
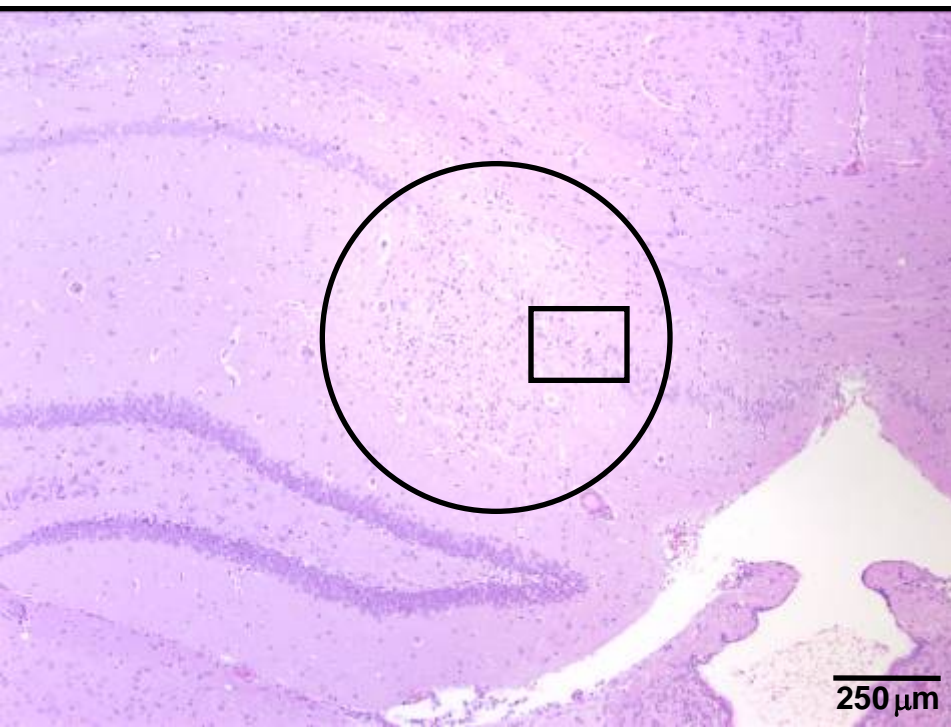24-month-old female hamster



Necrosis

- Necrosis with gliosis in CA1 region of the hippocampus

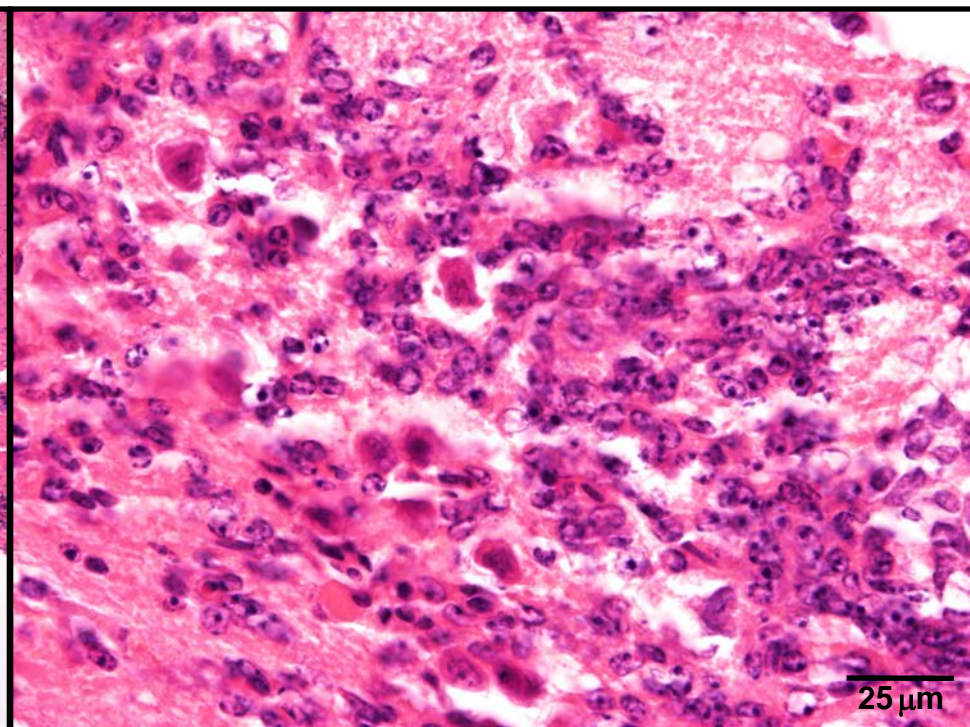
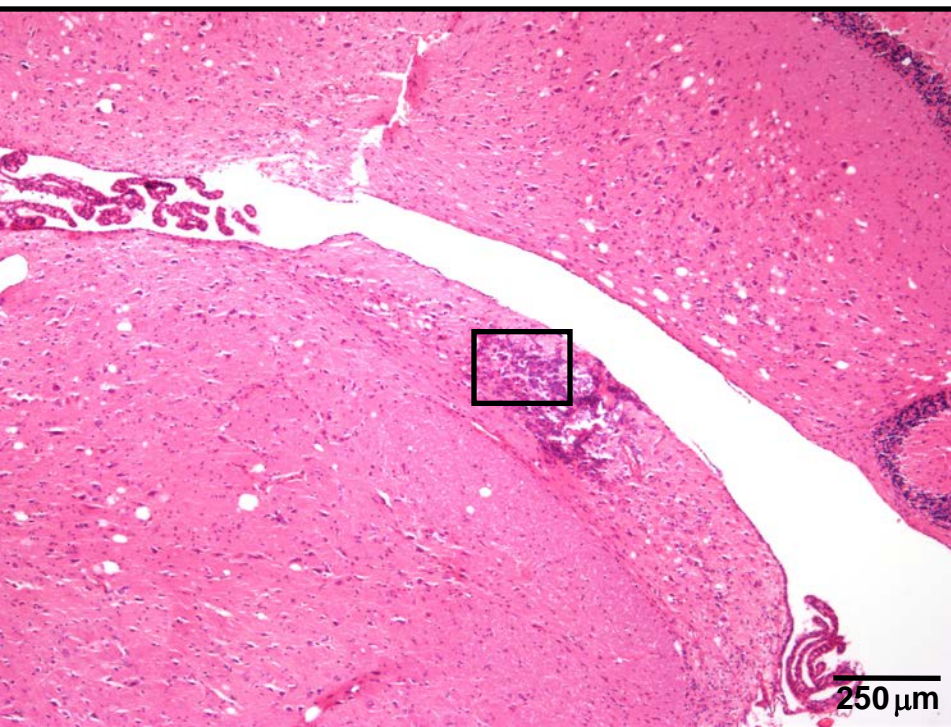
24-month-old male hamster



What's Your Diagnosis?

- Focal accumulation of cells in the cochlear nucleus of the medulla oblongata

24-month-old female hamster



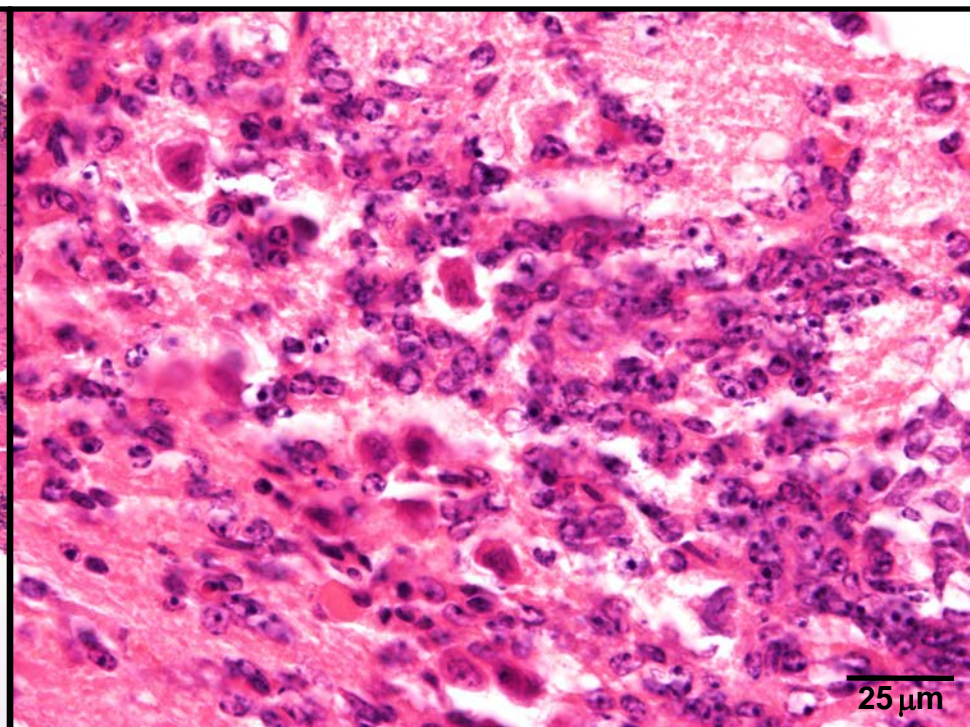
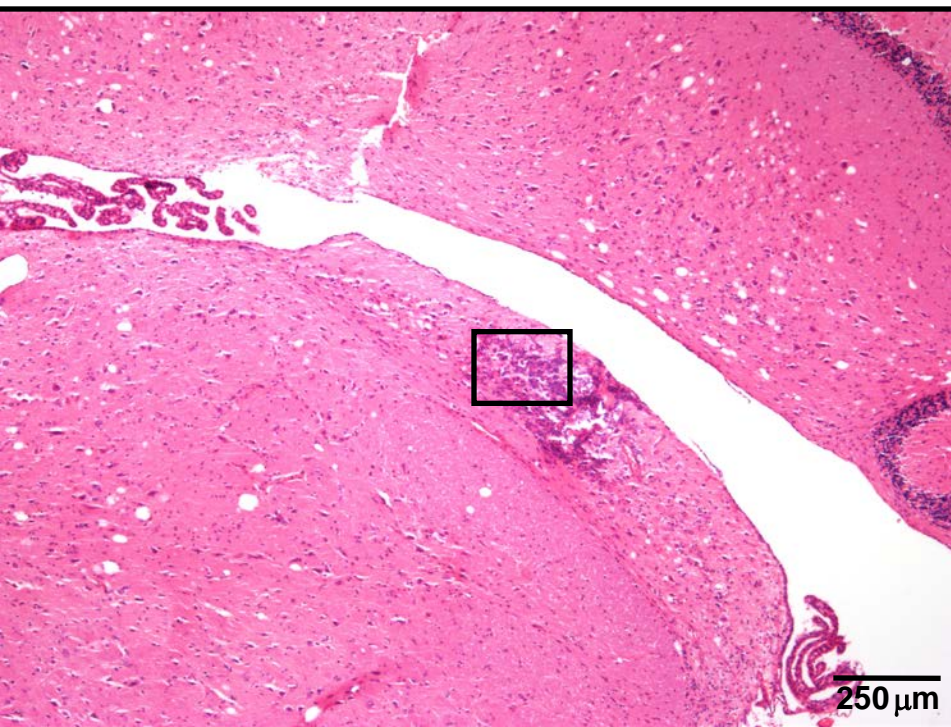
What's Your Diagnosis?

1. Granulomatous inflammation
2. Ectopic precursor cells
3. Histiocytic neoplasia
4. Neoplasia of glial cells
5. Glial nodule

Ectopia

2. Ectopic precursor cells for neurons and/or glial cells ?

24-month-old female hamster



Summary


- **Age-related findings**
 - Neuropil vacuolization, mineralization
 - Deposition of neuronal lipofuscin (age pigment), lipopigment, and meningeal melanin/hemosiderin, tumors
- **Age-independent findings**
 - Mast cells, melanocytes
- **Incidental findings**
 - Inflammation, Necrosis, Spheroids, Ectopia

Conclusion

- **No animal model for Alzheimer's disease**
 - Lack of characteristic lesions
- **Animal model for vacuolization and mineralization**
 - Other mammalian species affected
 - Clinical significance unknown
 - Mineralization associated with inflammatory conditions, hypoxic-ischemic and excitotoxic injury*
- **Mast cells physiological residents in brain**
 - Similar to other mammalian species
 - Possibly responders to neuroinflammatory diseases and hypoxia-ischemia#

*Oliveira et al., 2003; Towfighi et al., 1991

#Theoharides and Cochrane, 2004; Jin et al., 2009



Acknowledgements

**Nycomed
Deutschland GmbH**
(Financial support)

Colleagues
Annika Lehmbecker
Christina Puff
Ilka Imbschweiler
Verena Haist

Technical staff

Volker Rehse
Karoline Walter
Uta Dörfel
Claudia Blum
Anja Schulze
Isabell Bleeker
Margarethe Schleiss
Bettina Buck
Kerstin Rohn
Petra Grünig



**Thank you
for your
attention**