



CONTINUING EDUCATION IN TOXICOLOGIC PATHOLOGY REPRODUCTIVE SYSTEM

Third Conference

ORGANIZED BY SOCIETY FOR TOXICOLOGIC PATHOLOGY IN INDIA (STPI)

OCTOBER 29-31, 2010

The Atria Hotel, # 1, Palace Road, Bangalore - 560 001



AURIGENE

Accelerating Discovery



citizen industries



maccine

SIEMENS

Samitek Instruments



Instem™

Information Solutions For Life

MPI
RESEARCH

Customized.
Responsive.
On-Time.™

BIONEEDS
Laboratory Animals & Preclinical Services

SDS
Special Diets Services
customerservices@toquimen.eu

IKA®

ATNT

A leading research products company in India
An ISO 9001:2000 Company

harlan™
Helping you do research better

Caliber®
Technologies Pvt. Ltd.

intox

torrent

ConneXios

glenmark
A new way for a new world

LABCON
SCIENTIFIC INSTRUMENTS
PRIVATE LIMITED

TOWA

NUTRILAB®

Vishnu Traders



RCC
Linking science to progress

APPROACH TO EVALUATION OF THE FEMALE REPRODUCTIVE TRACT*

* for Toxicity Studies

Karen S. Regan, DVM, DABT, Dipl ACVP
Research Pathology Associates, LLC

Female Reproductive Tract Evaluation

- Pitfalls of microscopic evaluation of the female reproductive tract
 - Test article-induced changes are often subtle
 - Changes usually are not associated with clinical signs (in routine toxicity studies)
 - Detection is complicated by the constant change in microscopic appearance due to the estrous cycle
 - Detection further complicated by sensitivity of the cycle to environmental cues

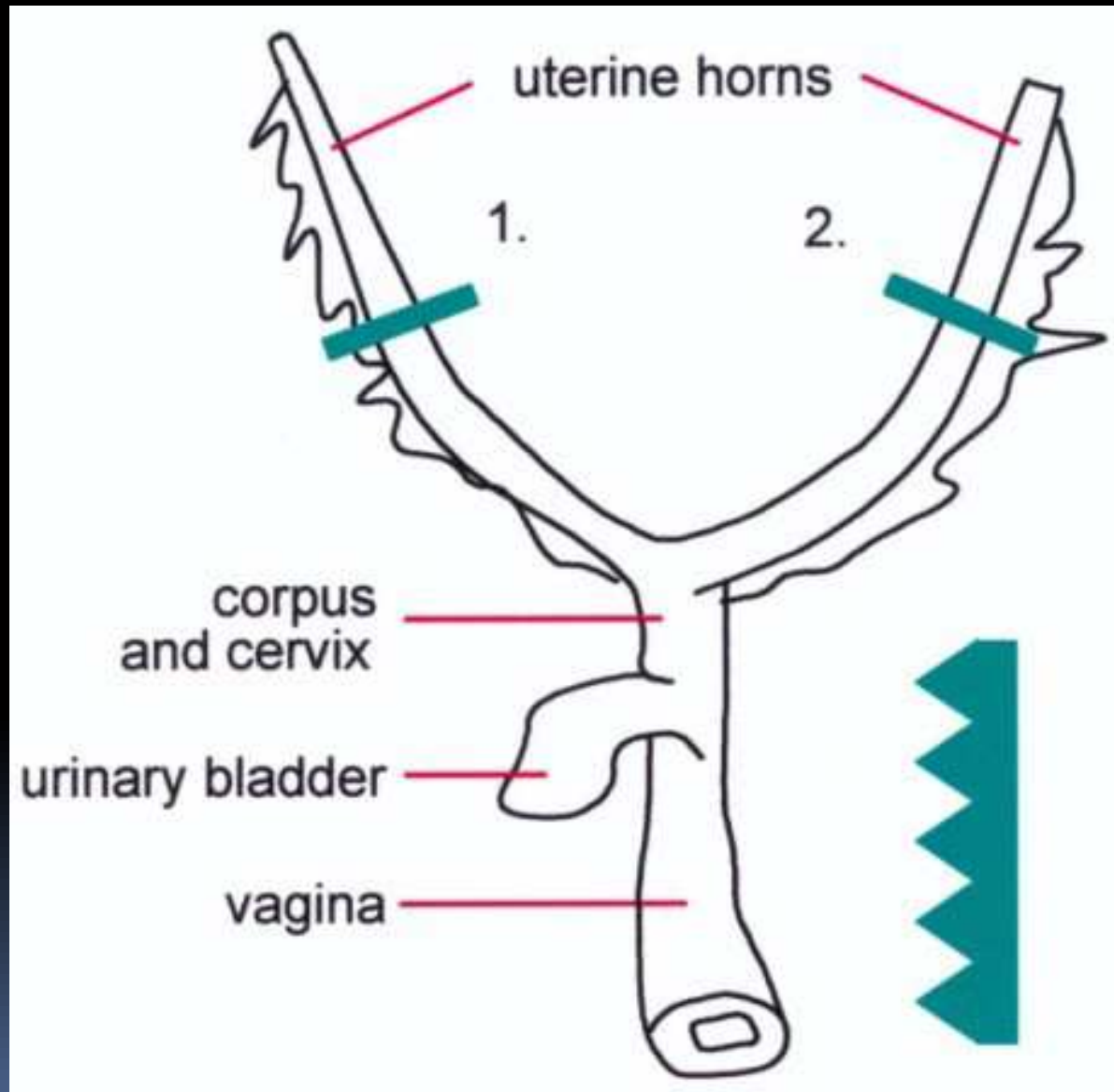
Female Reproductive Tract Evaluation

- More pitfalls
 - Detection further complicated by age-related senescence that can start by 5 months of age
 - Changes in different reproductive tract organs are often inter-related and even inter-dependent
 - Mixed hormonal effects (i.e. estrogen antagonist and agonist effects) may be present in different reproductive organs or even the same organ
 - Spontaneous lesions are common and mimic test effects

Female Reproductive Tract Evaluation

- How can morphologic evaluation be made consistent (and relevant)
 - Consistent trimming
 - Know the basic physiology
 - Mentally stage all the animals
 - Careful examination of controls

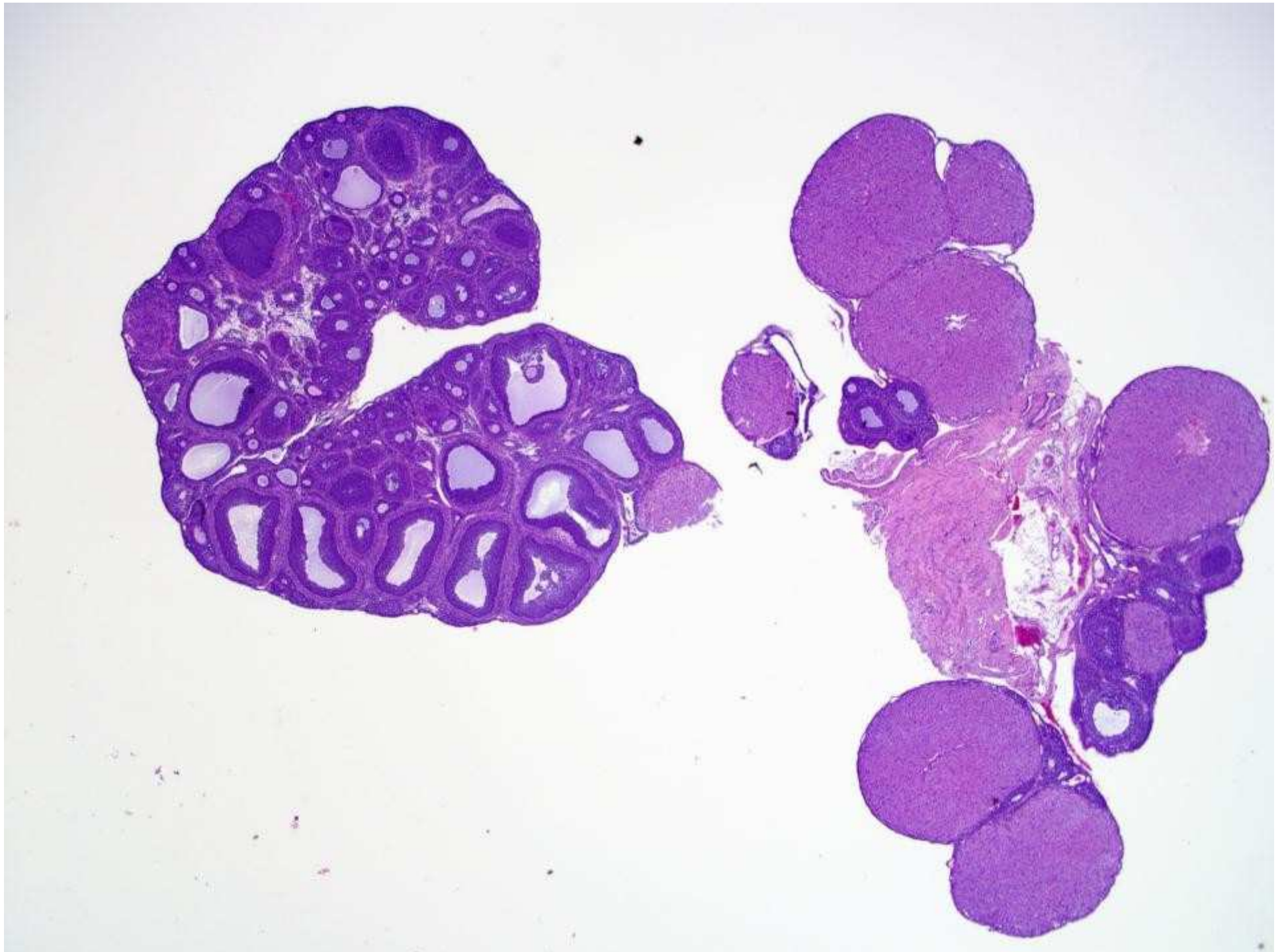
Recommended Sectioning



from Kittel et al 2004

Female Reproductive Tract Evaluation

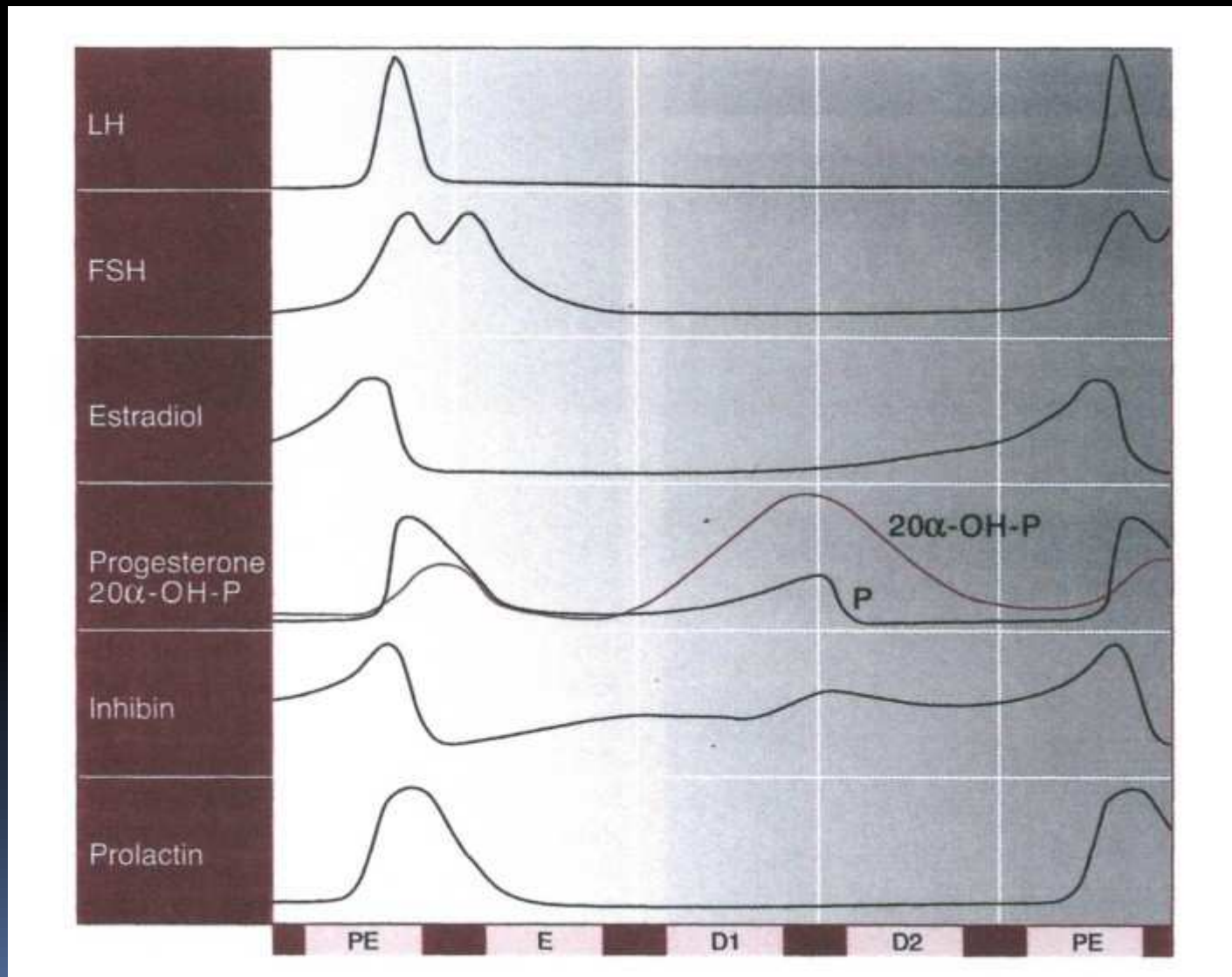
- Consistent sampling at histology (goRENI)
 - Central sections through entire ovary, longitudinal if possible
 - Transverse sections of each uterine horn
 - Longitudinal section of uterine body, cervix and mid and cranial vagina (critical)



Female Reproductive Tract Evaluation

- Have a handle on the basic physiology and the corresponding anatomical appearance
 - Needed for:
 - Staging the cycle
 - Interpretation of changes
 - Conveying information
 - Knowing what to expect improves the likelihood of detecting a change

Hormonal Profile, 4 Day Cycle



from Maeda et al 2000

Female Reproductive Tract Evaluation

- Mentally stage every animal
 - **Mental** staging should be done on animals from studies of all lengths, even chronic studies
 - In these studies, 'staging' means examination with awareness of the hormonal state of each of the tissues
 - It is usually not possible or necessary to assign a specific estrous cycle stage to animals in studies >3 months duration
 - Animals often not cycling due to senescent changes

Female Reproductive Tract Evaluation

- Mentally stage every animal
 - For studies ≤ 3 months duration, may assign a specific estrous cycle stage
 - Large % of control animals still cycling
 - Uterus and vagina are most useful
 - Morphologic appearance of the ovary can confirm the stage but should not be used by itself for staging

Female Reproductive Tract Evaluation

- Staging short term studies
 - Examine vagina first, then uterus, ovaries and other available tissues
 - Determine if the morphologic appearance of the other tissues is consistent with the hormonal state of the vagina
 - The cycle is a continuum and the tissue morphology may not fit neatly into a single stage
 - By convention, the later stage is designated

Female Reproductive Tract Evaluation

- Perform a thorough examination of controls
 - Changes that look like effects are often present in controls
 - Senescent changes can occur in relatively young animals (90 day and occasionally even 30 day studies)

